

# Elastic Intramedullary Nailing




ORTHOPEDIC  
**CATALOGUE**

## Products


### 9.1 Elastic Nail (Titanium)

#, .,5B"C	(!"5B"C	)
2.0	440	<b>9.1.TI01</b>
2.5	440	<b>9.1.TI2.</b>
3.0	440	<b>9.1.TI03</b>
3.5	440	<b>9.1.TI04</b>
4.0	440	<b>9.1.TI05</b>

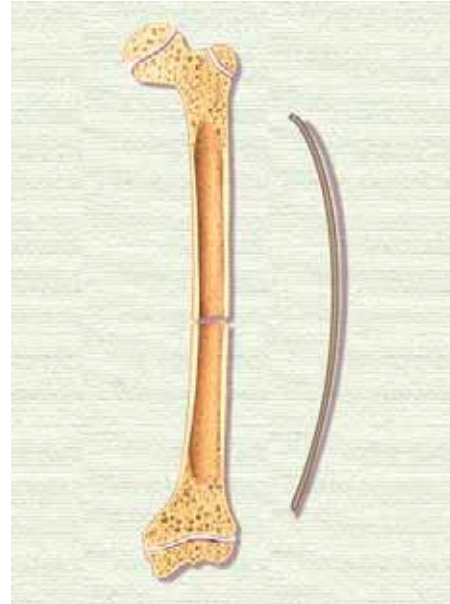
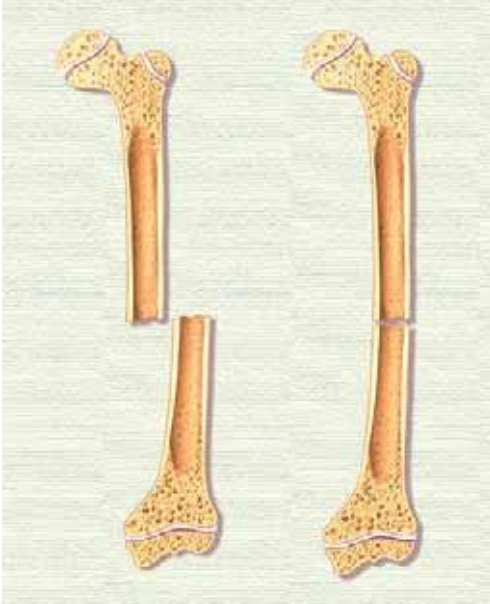


### 9.2 Elastic Nail Instruments Set

) -	.5 )(-#.#(15) 9	(#.-
9.2.01	Insertor with Universal Chuck	1
9.2.2.	Locking Pliers	1
9.2.03	Bar, for Small F-Tool	1
9.2.04	3.2 mm/4.5 mm Double Drill Sleeve	2
9.2.05	2.2 mm/2.7 mm Double Drill Sleeve	2
9.2.06	Drill bit 2.7 mm	1
9.2.07	Drill bit 3.2 mm	1
9.2.08	Drill bit 4.5 mm	1
9.2.09	Ruler	1
9.2.10	Curved AWL	1
9.2.11	Pincers for taking out pins	1
9.2.12	Connector (Straight)	1
9.2.13	Detachable Slide Hammer	1
9.2.14	Pin Cutter for Nail	1
9.2.15	Aluminum Box for Elastic Nailing Instruments	1

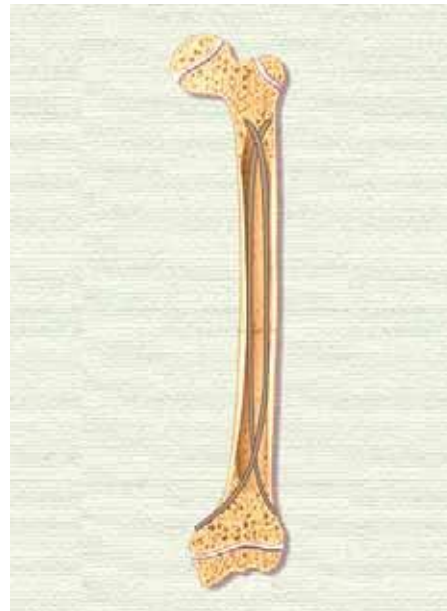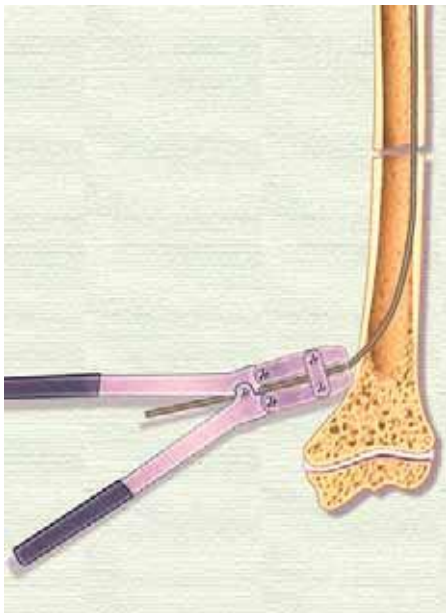
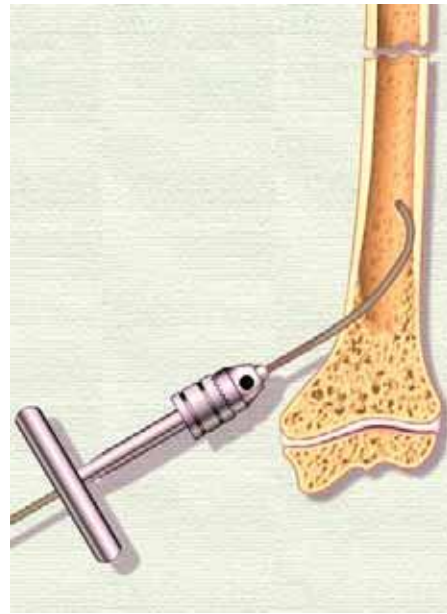
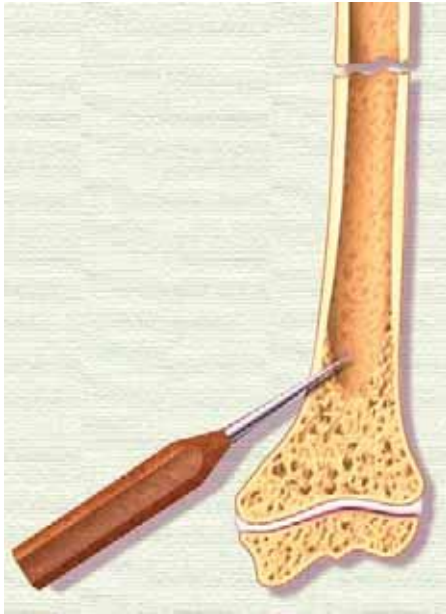


**Surgical Technique for Pediatric Femur Fractures**



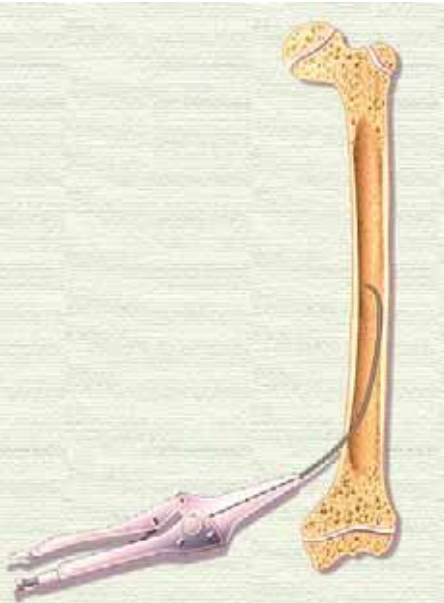
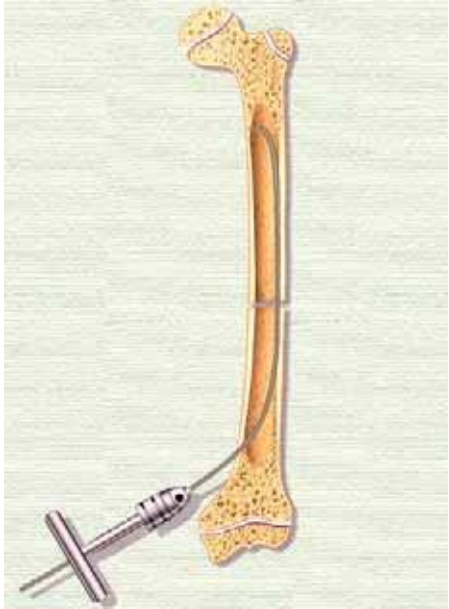
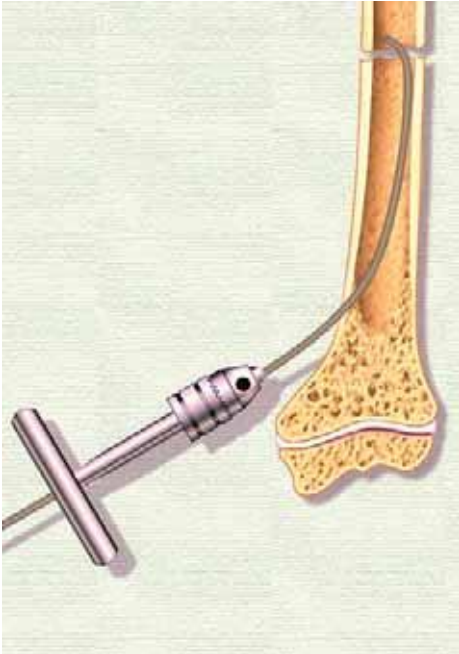
# GEOORTHO Elastic Intramedullary Nailing

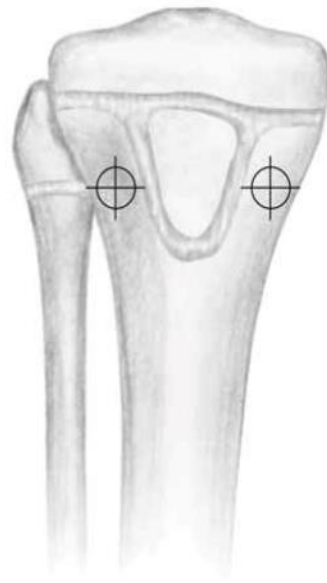## Surgical Technique for Pediatric Femur Fractures



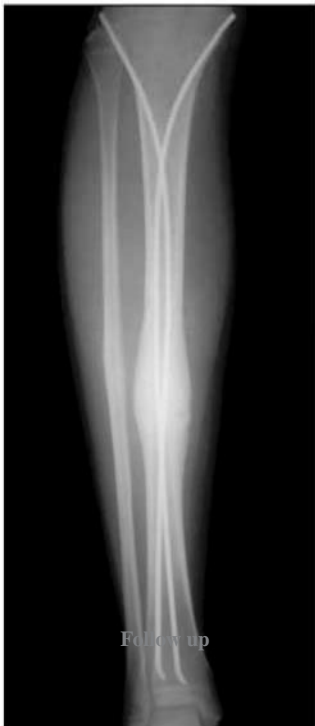# GEOORTHO Elastic Intramedullary Nailing

## Surgical Technique for Pediatric Femur Fractures





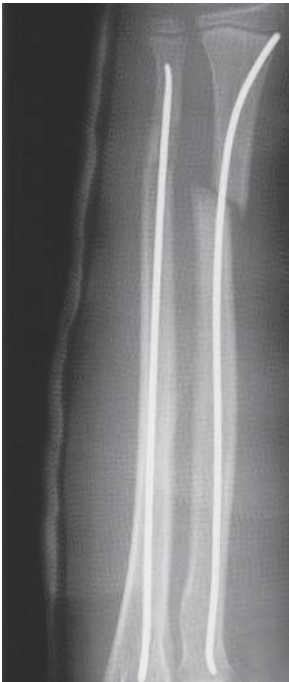Lateral view



Follow up

# **GEOORTHO Elastic Intramedullary Nailing**

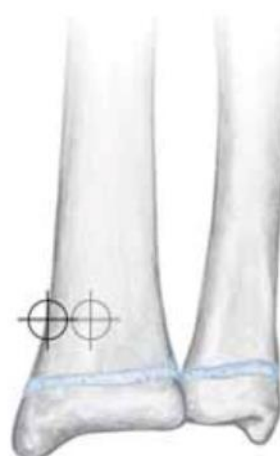## **Surgical Technique for Forearm Fractures**



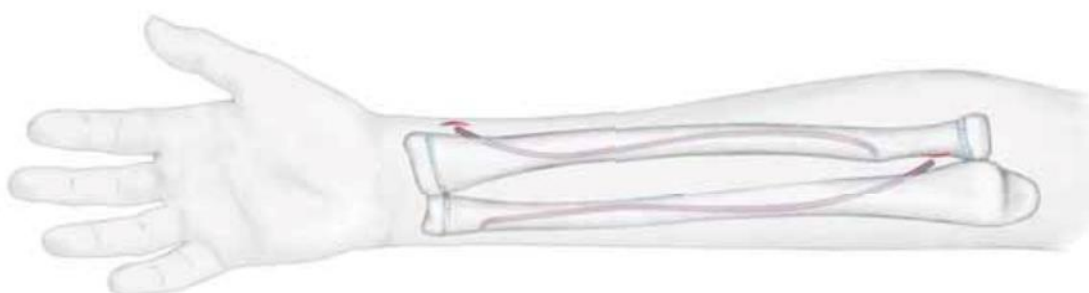
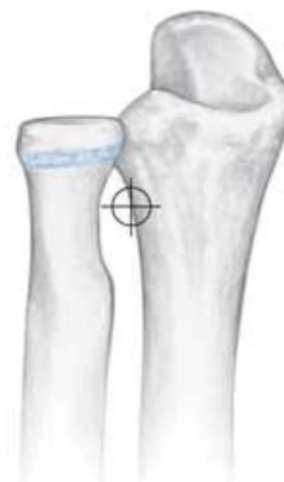**Surgical Technique for Forearm Fractures**



*Caution: Be aware of the extensor tendons and superficial radial nerve.*



The antegrade entry point in the ulna can be either at the posterior aspect of the olecranon or a lateral approach through the proximal metaphysis. The retrograde entry point in the ulna is through the distal metaphysis.

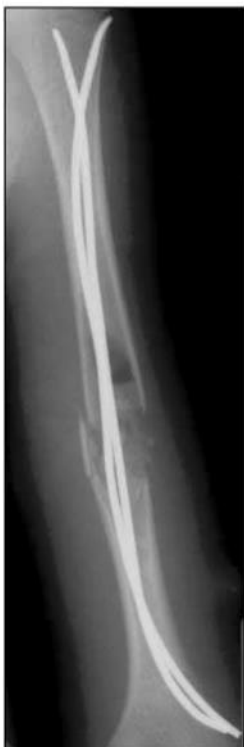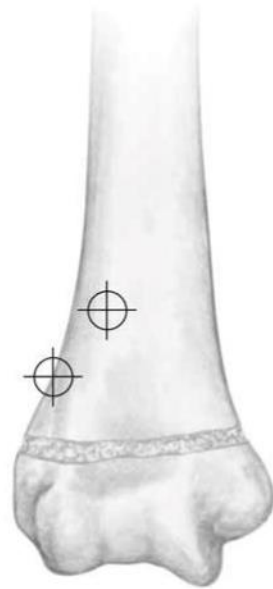




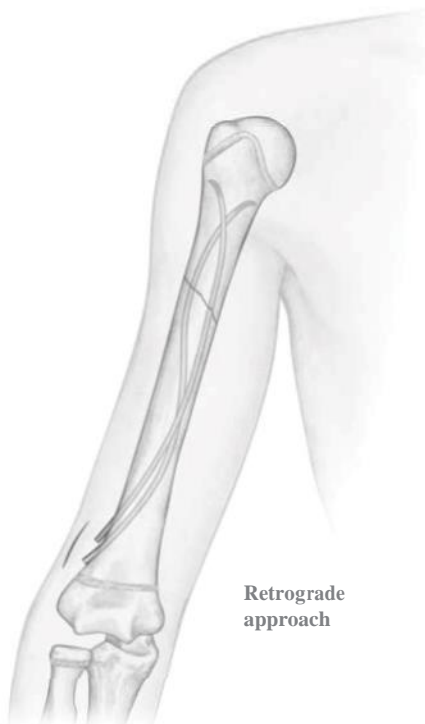# GEOORTHO Elastic Intramedullary Nailing

## Surgical Technique for Humerus Fractures

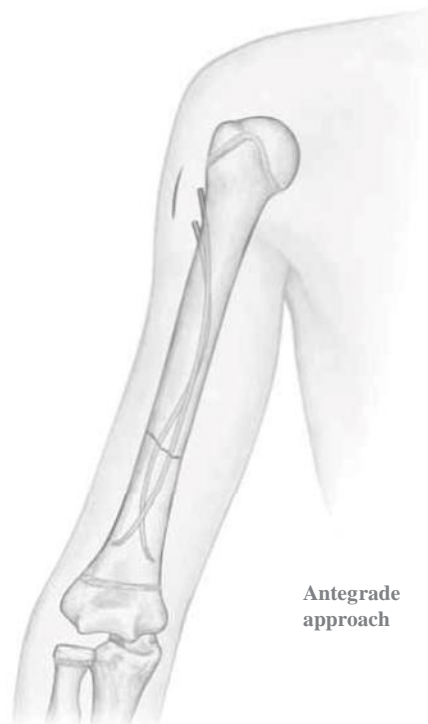*Caution: Be aware of the position of the radial nerve in relation to the fracture.*



Follow up



Retrograde approach



Antegrade approach